

ORIGINAL ARTICLE

Vogt-Koyanagi-Harada Disease: Clinical and Demographic Characteristics of Patients in a Specialized Eye Hospital in Turkey

Pinar Ozdal, MD¹, Yasemin Ozdamar, MD¹, Alper Yazici, MD²,
Mehmet Y. Teke, MD¹, and Faruk Ozturk, MD¹

¹Ulucanlar Eye Education and Training Hospital Ophthalmology Clinic, Ankara, Turkey and ²Balikesir University Faculty of Medicine Department of Ophthalmology, Balikesir, Turkey

ABSTRACT

Purpose: To evaluate clinical and demographic features of Vogt-Kayanagi-Harada disease (VKH) disease in Turkish patients and compare them with previously published data.

Methods: Demographic and clinical features of 32 patients diagnosed as VKH in a tertiary referral center were retrospectively reviewed.

Results: The mean age at presentation was 33.6 ± 10.4 years. Seventy-five percent of the patients were female and 62.5% of the patients presented during the last 2 years. The disease was complete in 31.2%, incomplete in 50%, and probable in 18.8% of the patients. The clinical course was acute in 50%, chronic recurrent in 34.4%, and chronic in 15.6%. The most common findings were bilateral serous retinal detachment \pm papillitis in acute cases and retinal pigment epithelial changes of the macula in chronic cases.

Conclusions: Although rare in Turkey, VKH disease seems to have increased during the last few years. The disease is incomplete and acute in half of the patients and has a quite good visual prognosis.

Keywords: Ocular involvement, treatment, uveitis, VKH, Vogt-Koyanagi-Harada disease

Vogt-Koyanagi-Harada (VKH) disease is an inflammatory disorder characterized by bilateral granulomatous panuveitis and extraocular manifestations, such as headache, meningismus, vitiligo, alopecia, and tinnitus.^{1–3} It has been suggested as a cell-mediated autoimmune disorder acting against melanocytes. Thus, the melanocytes present in every organ may get affected by VKH disease.^{4–7} The disease itself affects primarily individuals with greater skin pigmentation, like Asians, Hispanics, Middle Easterners, Native Americans, and Asian Indians.^{8,9} The presence of extraocular manifestations may vary according to the stage of the disease and ethnical differences. Generally, the neurologic and auditory manifestations appear first, followed by ocular and finally the cutaneous findings.^{8,10} The presence and the number

of these manifestations provide the categorization of the disease as complete, incomplete, and probable using the revised diagnostic criteria.⁸

The disease has a course with prodromal, acute uveitic, chronic, and chronic recurrent stages. As a result of the recurrent ocular inflammatory attacks, ocular complications such as cataract, glaucoma, subretinal neovascularization, subretinal fibrosis, epiretinal membrane formation, macular atrophy, and pigmentary degeneration are common during the disease course.^{1,3,10–14} The occurrence of ocular complications increases with the frequency of ocular inflammatory attacks and is associated with worse visual prognosis.^{1,2,11}

Clinical features of VKH significantly differ in various ethnic populations.^{15–20} In this study, the

Received 19 August 2013; revised 8 October 2013; accepted 14 October 2013; published online 9 December 2013

Correspondence: Pinar Ozdal, MD, Ulucanlar Eye Training and Research Hospital, Ulucanlar cad. No: 59, Altindag, Ankara, Turkey. E-mail: pinarozdal@hotmail.com

clinical characteristics and visual outcomes of VKH disease in Turkish patients admitted or referred to a specialized eye hospital were evaluated.

MATERIALS AND METHODS

A retrospective review of the files of patients who were admitted to the uveitis department of a specialized eye hospital between 1997 and 2012 was performed. The diagnosis was made according to revised diagnostic criteria for VKH disease.⁸ Thirty-two patients who fulfilled these criteria were included to the study. A complete ophthalmological examination, including measurement of best corrected visual acuity (BCVA) and intraocular pressure, slit-lamp biomicroscopy, fundus examination using +90 diopter lens, ultrasonography, and fluorescein angiography (FA), was performed in all and optical coherence tomography (OCT) was performed in 26 patients who presented after the availability of the OCT in our hospital. Additional laboratory and radiological investigations were performed to rule out other possible conditions, such as ocular sarcoidosis, posterior scleritis, systemic lupus erythematosus, and uveal effusion syndrome. All patients were questioned for the history of ocular trauma or surgery and the presence of extraocular symptoms.

Complete blood count with differential, biochemical analysis, urinalysis, erythrocyte sedimentation rate, antinuclear antibody, serum angiotensin-converting enzyme level, chest radiography, and syphilis serology were done in all patients. Data including the age at presentation, sex, follow-up period, ocular and extraocular findings, course of the disease, complications, and treatment choices were noted. The disease was classified as complete, incomplete, and probable VKH according to revised diagnostic criteria.⁸ Ocular involvement was staged as acute uveitis in patients presenting with early manifestations of the disease (diffuse choroiditis, focal areas of subretinal fluid, bullous serous retinal detachment, vitreous inflammation, optic disk hyperemia), whereas patients presenting with late manifestations of the disease (sunset glow fundus, nummular depigmented chorioretinal scars, retinal pigment epithelium (RPE) clumping/migration) were staged as having chronic (convalescent) disease. Patients with ocular findings consistent with chronic stage and additional active anterior uveitis were considered as being in chronic recurrent stage.

Patients presenting in the acute stage were treated with high-dose intravenous pulse methylprednisolone therapy (1 g/day for 3–5 days, depending on clinical response) intravenously followed by oral methylprednisolone (1 mg/kg) with gradual tapering. Tapering schedule and the duration of corticosteroid therapy were individualized for each case and lasted

for at least 4 months. In patients presenting with chronic recurrent stage, the therapy was always started with immunosuppressive and oral corticosteroid therapy. As for the acute cases, duration and rate of drug tapering was case specific and planned according to clinical response. Patients who presented with clinical signs of chronic stage without any active inflammation were either followed without treatment or treated with an immunosuppressive agent to prevent the recurrence. Treatment response was assessed with clinical evaluation and OCT and/or FA.

Data were analyzed with SPSS 16.0 (SPSS Inc., Chicago, IL, USA). The study was conducted under the approval of institutional ethics committee in accordance with the principles Declaration of Helsinki.

RESULTS

The mean age at presentation was 33.6 ± 10.4 (12–65) years and the mean follow-up period was 39.1 ± 42.3 (5–180) months. Three patients (9.4%) were ≤ 16 years old. Although the study period was between 1997 and 2012, 20 of 32 (62.5%) patients presented during the last 2 years. Twenty-four patients (75 %) were female with an M/F ratio of 1/3. As all patients had bilateral involvement, the number of eyes included in this study was 64. The disease was bilateral at presentation in 31 patients (96.9%), whereas 1 patient had the second eye involved 2 months later. The diagnosis of VKH was made following ocular involvement in all patients. Sixteen patients (50%) presented at the acute uveitis stage, 11 patients (34.4 %) at the chronic recurrent stage, and 5 (15.6%) at the chronic (convalescent) stage. Four of the patients (25%) who presented at the acute stage had recurrent anterior uveitis attack(s) during the follow-up that turned into the chronic recurrent stage of the disease. Of the 16 patients who presented with acute uveitis, 4 (25%) had bilateral hyperemia and edema of optic nerve head (papillitis) and 12 (75%) had bilateral serous retinal detachment \pm papillitis.

Most of these patients developed late ocular manifestations of the disease during the follow-up period. Among these manifestations, RPE changes of the macula in 44/64 eyes (68.8 %), sunset-glow fundus in 40/64 eyes (62.5%), nummular yellow-white, well-circumscribed lesions in the peripheral retina in 30/64 eyes (46.9%), and severe retinal pigment epithelial clumping in 12/64 eyes (18.8%) were observed. Sunset glow fundus was observed at presentation in 5 patients (10 eyes) with chronic stage and in 8 patients (16 eyes) with chronic recurrent stage. This clinical finding developed during the follow-up period in another 7 patients (14 eyes) who presented with the acute stage. An additional 4 patients (8 eyes) in the

TABLE 1. Number and percentages (*n* (%)) of ocular findings in eyes according to the course of the disease.

	Chronic	Chronic recurrent	Acute ^a	Total
Vitritis		8 (12.5)	23 (35.9)	31 (48.4)
Exudative retinal detachment			24 (37.5)	24 (37.5)
Papillitis		4 (5.1)	14 (23.0)	18 (28.1)
Sunset glow fundus	10 (15.6)	16 (25.0)	14 (21.9)	40 (62.5)
Retinal pigment epithelial changes of the macula	8 (12.5)	14 (21.9)	22 (34.4)	44 (68.8)
Yellow-white, well circumscribed lesions in the peripheral retina	10 (15.6)	14 (21.9)	6 (9.4)	30 (46.9)
Cataract	2 (3.1)	10 (15.6)	4 (6.3)	16 (25.0)
Glaucoma		8 (12.5)		8 (12.5)
Choroidal neovascular membrane		3 (4.7)		3 (4.7)
Subretinal fibrosis		2 (3.1)		2 (3.1)

^aAt follow-up.

TABLE 2. The frequency of extraocular findings in VKH patients.

Extraocular findings	No. of patients (%)
Headache	22 (68.7)
Tinnitus	21 (65.6)
Dysacusia	9 (28.1)
Alopecia	9 (28.1)
Poliosis	2 (6.2)
Vitiligo	4 (12.5)

acute stage developed macular RPE changes without sunset glow fundus during the disease course. Thus, chronic changes developed during the follow-up in overall 22/32 eyes of 11/16 (68.8%) patients who presented with the acute stage. Of these 11 patients, 7 (63.6%) received high-dose corticosteroids immediately after their presentation and the remaining 4 were treated late or inadequately because of the diagnostic delay due to late referral. Therefore, although treated properly, 7/16 (43.8%) of acute stage patients developed chronic ocular findings. Ocular findings classified according to the course of the disease are listed in Table 1.

Among the extraocular findings, headache (68.7%) and auditory problems (tinnitus 65.6% and dysacusia 28.1%) were the most common and were coincident with the onset of ocular disease. Others were alopecia (28.1%), poliosis (6.2%), and vitiligo (12.5%), observed in the chronic or chronic recurrent stage. All extraocular findings noted in our patients are documented in Table 2.

According to revised diagnostic criteria, 10 patients (31.2%) had complete, 16 patients (50%) had incomplete, and 6 patients (18.8%) had probable VKH disease. Demographic and clinical characteristics of the patients are summarized in Table 3.

Among 16 cases who presented with the acute stage, 3 patients (18.75%) developed the complete form of the disease during the follow-up, whereas 13 (81.25%) had either incomplete (10 patients, 62.5%) or probable forms (3 patients, 18.75%) of the disease. From a different point of view, of the 10 patients with complete disease, 7 (70%) presented with chronic

TABLE 3. Demographic and clinical characteristics of the patients.

Mean age (range)	34 (12–65) years
Gender, <i>n</i> (%)	
Male	8 (25)
Female	24 (75)
Classification of the disease, ^a <i>n</i> (%)	
Complete	10 (31.2)
Incomplete	16 (50)
Probable	6 (18.8)
Course of the disease, <i>n</i> (%)	
Acute	16 (50)
Chronic recurrent	11 (34.4)
Chronic	5 (15.6)

^aAccording to revised diagnostic criteria [8].

recurrent or chronic stage, and 3 (30%) presented with acute stage.

Of the 16 patients who presented with chronic or chronic recurrent stage, 8 (50%) were previously diagnosed with either Behcet disease (3 patients) or idiopathic uveitis (5 patients) and the remaining 8 presented for the first time. Patients misdiagnosed with Behcet disease were previously treated with an immunosuppressive + corticosteroids combination, whereas the remaining 13 patients were either treated with low-dose systemic and/or topical corticosteroids or not treated.

Cataract (16 eyes, 25%), glaucoma (8 eyes, 12.5%), choroidal neovascular membrane (3 eyes, 4.7%), and subretinal fibrosis (2 eyes, 3.1%) were the ocular complications that we observed. Choroidal neovascular membrane and subretinal fibrosis were present in both eyes of the 13-year-old patient at presentation (patient 6). Another patient developed choroidal neovascular membrane during the follow-up period (patient 3).

Regarding imaging methods, FA was performed in all, OCT was performed in 26, and ultrasonography was performed in 9 patients at presentation. Besides the clinical findings, OCT was the most frequently used technique for monitoring the therapeutic response in acute cases (see Figure 1). When clinically

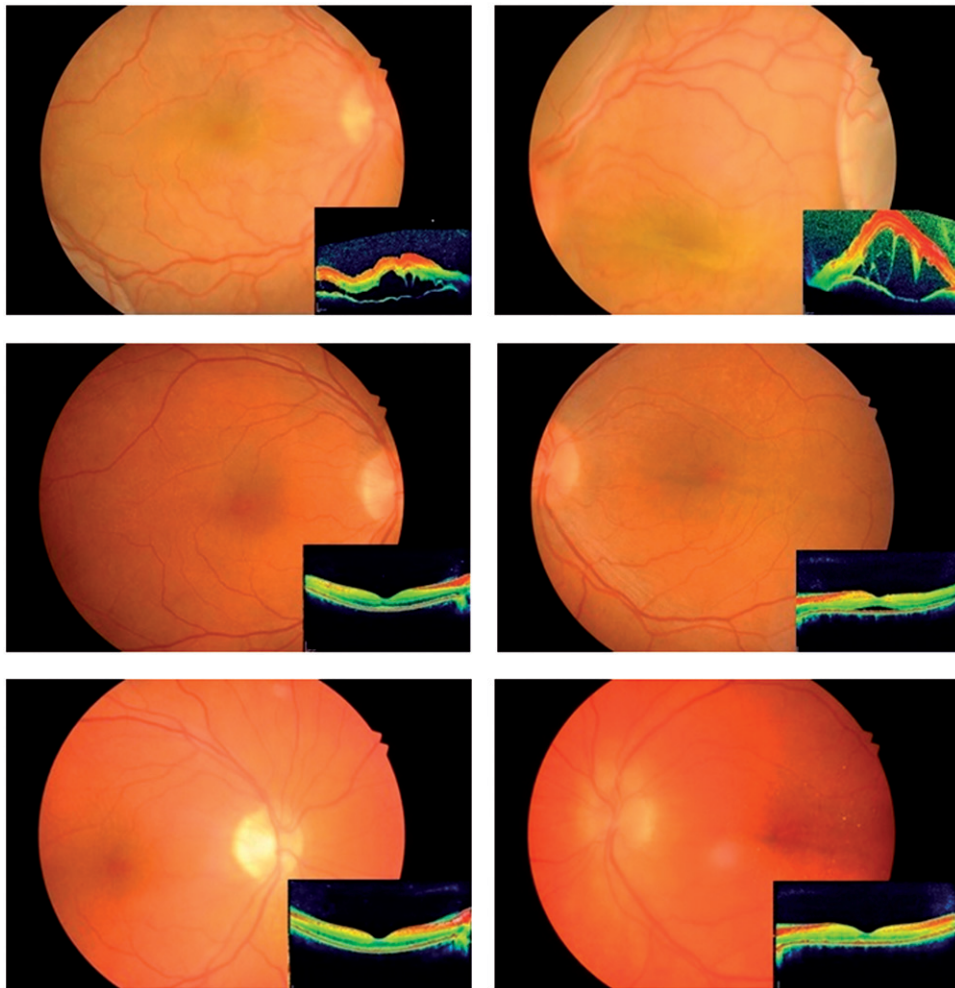


FIGURE 1. OCT is a useful tool both to demonstrate the serous detachment and to monitor the treatment response. The clinical improvement of a patient presented at the acute stage is confirmed by OCT images.

quiescent disease was achieved, FA was repeated to confirm the clinical findings.

The rates of eyes having 20/200 or worse BCVA at presentation and at last examination were 43.8 and 17.2%, respectively. The rates of eyes having BCVA of 20/40 or better were 35.9 and 73.4%, respectively. After proper treatment the rates of eyes having 2 or more lines of increase in BCVA was 59.3% (38 eyes) and decrease in 6.3% (4 eyes). All eyes with decreased visual acuity were in the chronic recurrent stage. Two of these eyes had uncontrolled glaucoma and underwent a glaucoma surgery. The visual acuity decreased because of severe macular pigmentation in one eye and macular scarring due to choroidal neovascular membrane in another one eye.

Intravenous high-dose methylprednisolone followed by a long-term oral corticosteroid therapy (CS) \pm immunosuppressive therapy was preferred in all acute cases. Immunosuppressive \pm oral CS therapy was the treatment of choice in chronic recurrent cases. Azathioprine and cyclosporine were the most commonly used immunosuppressive agents.

Methotrexate was the treatment of choice in one childhood patient. A total of 19 patients (59.4%) used immunosuppressive agents as monotherapy or combined therapy. No ocular inflammatory attack in 23 patients (71.9%), ≥ 2 attacks in 6 patients (18.8%), and 1 attack in 3 patients (9.3%) have been observed during the follow-up period. Treatment modalities and rate of recurrences for each case are presented in Table 4.

DISCUSSION

Prevalence and clinical characteristics of VKH disease vary among different nations and ethnicities. From this point of view, various studies have been conducted to demonstrate the characteristics of the disease in different regions of the world. These studies were mostly carried out in referral centers due to the unique characteristics of VKH disease.^{16–20} In this study we also evaluated the characteristics of VKH patients among patients admitted to a single referral eye hospital.

TABLE 4. Treatment modalities and recurrence rates listed for each case.

Patient	Stage at presentation	Treatment modality (duration as months)	Complications during follow-up	Classification of disease	No. of Recurrence during follow-up	Inflammation control in long term	Initial diagnosis and treatment
1	Chronic recurrent	AZT (32) + CSA (9) + CS ^a (4)		Complete	4	Yes	Idiopathic panuveitis, low dose CS, 3 years
2	Acute	IV high-dose CS		Incomplete	None	Yes	
3	Chronic recurrent	AZT (86) + CSA (22) + CS ^a (5)	Choroidal neovascular membrane	Complete	4	Yes	Behcet disease, AZA + CS, 5 years
4	Chronic	AZT (20)		Complete	None	Yes	Uveitis Low-dose CS, 2 years
5	Chronic recurrent	AZT (40) + CSA (24) + CS	Glaucoma	Complete	3	No	Panuveitis Low-dose CS, 1 year
6	Chronic recurrent	AZT (36) + CS ^a (4) Intravitreal bevacizumab		Complete	None	Yes	Uveitis Topical CS only, 2 years
7	Acute	IV high-dose CS		Incomplete	None	Yes	
8	Chronic recurrent	AZT (9) + CS ^a (6)		Probable	None	Yes	
9	Acute	IV high-dose CS (12) + CS ^a (9)	Sunset glow fundus, macular RPE changes, retinal atrophic lesions, cataract	Incomplete	3	Yes	Uveitis Topical CS, 2 weeks
10	Acute	IV high dose CS	Sunset glow fundus, macular RPE changes, cataract	Incomplete	None	Yes	Papillitis IV high-dose CS, 3days
11	Acute	IV high dose CS		Probable	None	Yes	
12	Chronic	CSA (22)		Probable	None	Yes	
13	Chronic recurrent	Addition of AZT (12)		Probable	1	Yes	Behcet disease CSA + CS, 2 years
14	Chronic recurrent	CSA (12) + CS (9)	Glaucoma	Complete	4	Yes	Behcet disease AZT + CS, 5 years
15	Acute	IV high-dose CS + oral CS ^a (6)	Sunset glow fundus, macular RPE changes, retinal atrophic lesions	Probable	None	Yes	
16	Acute	AZT (55) + oral CS (4)	Macular RPE changes, retinal atrophic lesions	Incomplete	None	Yes	Papillitis due to Behcet disease AZT, 4 years + oral CS, 3 months
17	Acute	IV high-dose CS	Macular RPE changes	Incomplete	None	Yes	
18	Acute	IV high-dose CS (12) + CSA (6)	Sunset glow fundus, macular RPE changes	Complete	2	Yes	
19	Acute	IV high dose CS	Macular RPE changes	Incomplete	None	Yes	Panuveitis Oral CS, 1 month
20	Chronic recurrent	AZT (12) + CS (6)		Incomplete	None	Yes	Anterior uveitis, topical CS, 4 months
21	Chronic			Incomplete	None	Yes	

(continued)

TABLE 4. Continued

Patient	Stage at presentation	Treatment modality (duration as months)	Complications during follow-up	Classification of disease	No. of Recurrence during follow-up	Inflammation control in long term	Initial diagnosis and treatment
22	Acute	IV high dose CS MTX + oral CS ^a (4)		Incomplete	None	Yes	Central serous chorioretinopathy
23	Acute	IV high-dose CS Oral CS ^a (8)	Sunset glow fundus, macular RPE changes, retinal atrophic lesions	Incomplete	1	No	
24	Chronic recurrent	AZT(12) + oral CS ^a (6)		Incomplete	None	Yes	
25	Acute	IV high-dose CS AZT (6) + oral CS ^a (4)	Macular RPE changes	Incomplete	None	Yes	
26	Acute	IV high-dose CS AZT (10) + oral CS ^a (8)	Sunset glow fundus, macular RPE changes, retinal atrophic lesions	Complete	2	No	Uveitis Topical CS, 2 weeks
27	Chronic			Incomplete	None	Yes	
28	Chronic recurrent	IV high-dose CS AZT + oral CS ^a (4)		Complete	None	Yes	
29	Chronic			Incomplete	None	Yes	
30	Acute	IV high-dose CS + oral CS ^a (4)	Sunset glow fundus, macular RPE changes, retinal atrophic lesions	Incomplete	None	Yes	
31	Chronic recurrent	IV high-dose CS AZT (8) + oral CS ^a (4)		Incomplete	None	Yes	
32	Acute	IV high-dose CS + oral CS ^a (6)		Probable	None	Yes	

CS, corticosteroid; CSA, cyclosporine A; AZT, azathioprine; MTX, methotrexate; IV, intravenous.

^aCorticosteroids in gradually tapered dosage.

VKH patients who fulfilled the revised diagnostic criteria⁸ made up 2.7% of our uveitis patients. These rates are similar to those of the studies from United States (1–4%), India (2%), and Brazil (2.5%) and lower when compared to Japan (10.1%), Tunisia (7.5%), and Singapore (15.9%).^{21,22} In the study of Tugal-Tutkun et al. published in 2007 the frequency of VKH in Turkish patients was reported as 1.2%. Unlike ours, this study included the data of seven referral centers.¹⁶ Another interesting finding of our study was the increase in the frequency of VKH disease between 2010 and 2012. Of our patients, 62.5% presented during the last 2 years. In our previous study evaluating epidemiologic characteristics of 1028 patients between 1990 and 2008, the frequency of VKH disease was found to be 0.4%.²³ This may be explained by our increased awareness about the disease or unknown presumptive factors such as environmental factors.

VKH has been reported to predominate in female patients. In the current study three-quarters (75%) of patients were female, which is consistent with the literature.^{10,12,16} The mean age at presentation was 33.6 ± 10.4 years in our study, similar to most other studies.^{12,16,21,22} However, there are different studies with lower (25 years)¹⁵ and higher (44.7 years)²⁴ mean ages at disease presentation. The pediatric patients in our study composed 9.4% of all VKH patients. This rate is 13.4% in Saudi Arabia²⁵ and 15% in another study from Turkey.¹⁶

The clinical presentation of VKH, which is believed to be a T-cell-mediated autoimmune reaction against a melanocyte-related antigen, differs greatly in different ethnic populations.^{15–20} Patients may present with headache or hearing loss only or just with ophthalmologic complaints. To facilitate the diagnosis, two different diagnostic systems suggested by Sugiura and the American Uveitis Society, both in 1978, have been widely used.^{3,26} In 2001, the International Committee on Vogt-Koyanagi-Harada Disease Nomenclature revised the diagnostic system and advocated the establishment of new diagnostic criteria.⁸ According to these revised criteria the disease has been categorized as complete, incomplete, or probable VKH based on the spectrum of manifestations seen. The probable disease can alternatively be referred as “ocular VKH disease.” In the current study the diagnosis was complete in 31.2%, incomplete in 50%, and probable in 18.8% of the patients. Similarly to our rates, Bykhovskaya et al.¹² reported 87.5% of definite cases, including complete and incomplete cases, and 12.5% of probable VKH cases. The rates in a review of 410 VKH patients revealed a result of 66.5% complete, 18.5% incomplete, and 15% probable VKH diagnosis.²⁷

Early admittance to hospital and proper immunosuppressive treatment may change the course of the disease and may delay the appearance of complete

form of the disease. Mostly the neurologic and auditory signs precede ocular involvement, and cutaneous signs appear later in the course of the disease. So according to the phase in which the patient is seen, the diagnosis may fall into the complete, incomplete, or probable category. In the current study, 18.75% of patients who presented at the acute stage developed cutaneous signs later and had the complete disease during the follow-up period. In other words, 70% of patients with complete disease presented with chronic stages of the disease. As most of the acute cases were treated with high-dose corticosteroids, this finding confirms the fact that early and aggressive treatment may prevent the development of complete VKH disease. However, our data showed that chronic ocular findings may develop even in properly treated patients. Among the acute stage patients developing chronic changes during the follow-up period, 63.6% were immediately treated with high-dose corticosteroid at presentation.

On the other hand, half of the patients with chronic or recurrent disease were misdiagnosed as either Behcet disease or idiopathic uveitis. The other half were not even aware of their disease and presented for the first time with the recurrent uveitis attack or were diagnosed incidentally during an eye examination. This finding enables us to comment that the chronic disease is more prone to develop in lately diagnosed and/or inadequately treated patients.

The most common extraocular finding in our patient population was headache (68.7%) followed by tinnitus (65.6%), dysacusia (28.1%), alopecia (28.1%), vitilligo (12.5%), and poliosis (6.2%). The distribution of extraocular findings in the current study and previous other studies is shown in Table 5. Headache was the most frequent extraocular finding both in our study and the above-mentioned studies. Similarly to the study by Tugal-Tutkun,¹⁶ dermatologic signs were less in Turkish patients compared to Chinese patients,²⁷ a finding supporting the importance of ethnicity in clinical presentation. On the other hand, tinnitus was a common finding (65.6%) in our study compared to previous studies, including the one from Turkey,^{16,27,28} showing that not only ethnical but also geographical factors are important in the frequency of manifestations.

TABLE 5. Comparison of the extraocular findings with previously published studies.

	Tugal-Tutkun ¹⁶	Yang ²⁷	Rao ²⁹	Current study
Headache	69	52.4 (meningismus)	49	68.7
Tinnitus	31	43.7	36	65.6
Dysacusia	16	29.3	32	28.1
Alopecia	11	39.8	18	28.1
Poliosis	13	36.6	28	6.2
Vitilligo	16	21.5	20	12.5

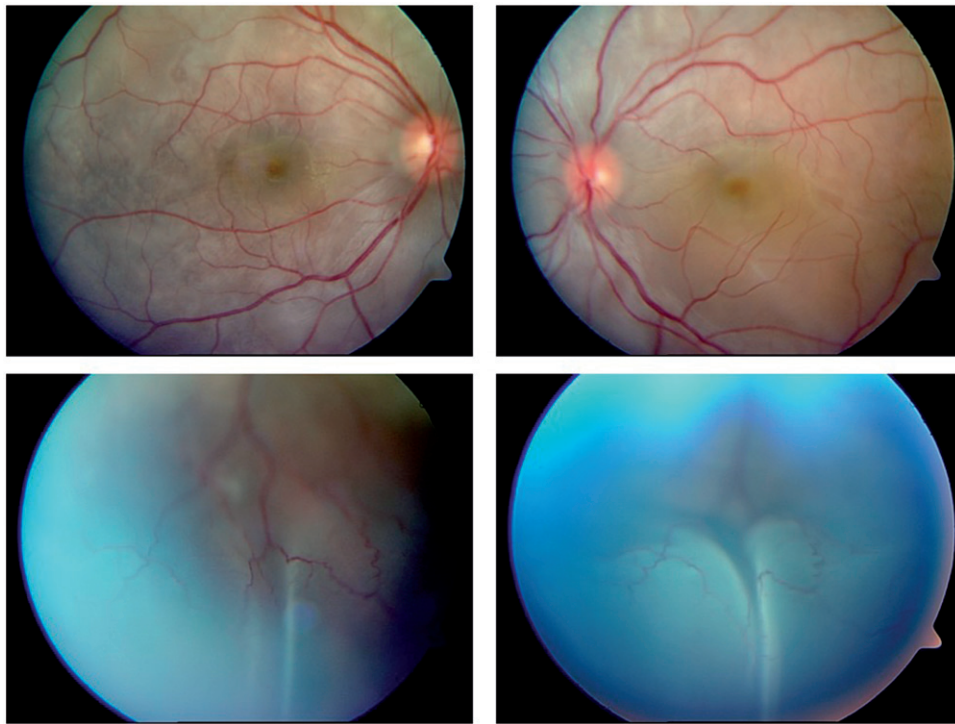


FIGURE 2. A VKH patient presenting at the acute stage with bilateral bullous serous retinal detachment.

Our patients mostly presented with bilateral exudative retinal detachment in the acute stage and with sunset glow fundus and macular pigment epithelial changes in chronic stages. In a multicenter study including different nations, Rao *et al.*²⁸ evaluated symptoms and signs of VKH patients and their predictive values for the diagnosis. They concluded that bullous detachment in acute cases and sunset glow fundus in chronic cases were distinguishing signs for VKH. See acute and chronic disease fundus findings of VKH in Figures 2 and 3, respectively.

Cataract (25.0%) was the most frequent complication in our population, consistent with the rates (13–53%) reported in the literature.^{1,10,16,16,21} Glaucoma was seen in 12.5% of our patients falling also in the range (1–29%) given by previous studies.^{1,10,16,16,21} Choroidal neovascular membrane and subretinal fibrosis, which are severe complications of the disease, were observed in both eyes of the same childhood patient at presentation. This patient had been treated only with topical corticosteroids until her presentation to our center. In addition to this patient, another one developed choroidal neovascular membrane in one eye during the follow-up period. Macular complications that we observed in 68.8% of patients had been reported to occur in a wide range from 1 to 40%.^{17,21,29} We should always remember that the time period between the disease onset and the diagnosis, the severity of the inflammatory process, the follow-up period, the extent of corticosteroid use, and even the mean age at

presentation are very important parameters that may cause a great variation in these results.

Since the disease causes several complications and macular and retinal changes, the visual acuity may decrease severely during the disease course. Final BCVA of 20/40 or better was achieved in 73.4% of the eyes, which is consistent with the literature.^{16,17,21,30} Khairallah *et al.*²¹ stated that poor visual outcome was associated with poor BCVA at presentation, presence of complications, and recurrences. In our study all of the 4 eyes in which the visual acuity decreased during the follow-up period had chronic recurrent disease. These eyes had either an uncontrolled glaucoma or a severe maculopathy. Unlike the studies reporting the BCVA at presentation as an important prognostic factor,^{10,15,21,31} Chee *et al.*¹⁹ stated that BCVA at 1 month after the treatment initialization was a more crucial parameter for visual prognosis. They suggested that if BCVA at the end of the first month of treatment was 20/200 or worse, treatment response of these patients should be considered not satisfactory and more aggressive treatment options should be considered.

The visual prognosis of VKH is favorable when an appropriate treatment is administered. Treatment strategies, ideal timing for the use of immunosuppressive agents, and the duration of the therapy are controversial issues. Administration of intravenous pulse or high-dose oral corticosteroids followed by an oral corticosteroid taper over 3–6 months is the most commonly used treatment strategy in VKH.³² Read *et al.*³³ suggested that both intravenous and

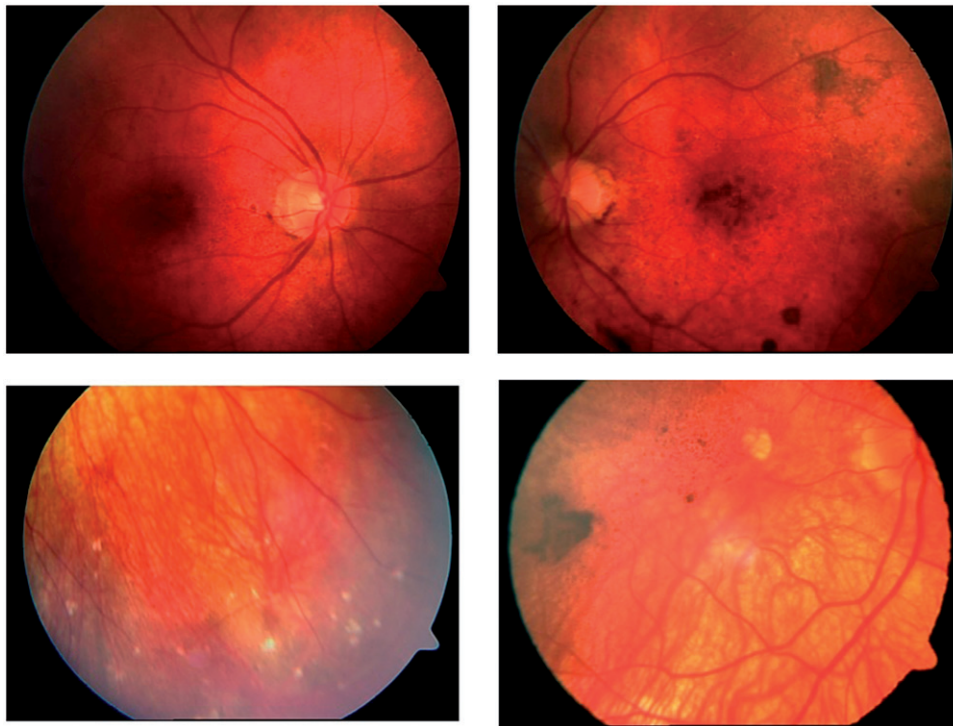


FIGURE 3. A VKH patient presenting at the chronic stage with sunset-glow fundus, macular RPE changes, retinal pigment epithelium clumping, and yellow-white well-circumscribed lesions in the peripheral retina.

oral administration of corticosteroids were equally effective. Although corticosteroids are very effective, their several ocular and extraocular complications limit their use in long-term. Traditionally, immunosuppressive agents are reserved for more refractory and severe cases.^{1,10,11} However, on the evidence-based medicine review regarding the safety and effectiveness of corticosteroids and immunosuppressive agents for the treatment of VKH, the American Uveitis Society has concluded that VKH requires immunosuppressive therapy as first-line treatment to control the inflammation.³⁴

We started immunosuppressive agents in 59.4% of the cases. This rate was 39.1% in Mondkar et al.,³⁵ 65% in Bykhovskaya et al.,¹² and 53% in Murthy et al.¹⁷ Murthy et al.¹⁷ stated that their rate of 68% in achieving final BCVA of 20/40 or better might be due to the higher rate of immunosuppressive use. Comparably with them, we achieved a final BCVA of 20/40 or better in 73.4% of patients. On the other hand, a BCVA of 6/18 or better was only seen in 15.4% in the study by Mondkar et al.³⁵ Azathioprine and cyclosporine, either as monotherapy or combination therapy, were the immunosuppressive agents that we preferred to use in VKH. Agarwal et al.³⁶ reported a rapid remission in a series of severe recalcitrant VKH cases in whom they used triple-agent therapy, including corticosteroids, azathioprine, and cyclosporine. A recent study compared the remission rate and steroid-sparing effect of two different combinations: cyclosporine + azathioprine

and cyclosporine + mycophenolate mofetil. Although not statistically significant, the first combination was found to be faster to reach remission and corticosteroid-sparing effect.³⁷

In conclusion, although rare in Turkey, the frequency of VKH disease has seemed to increase during the last few years with unknown presumptive reasons. Its diagnosis is mainly clinical and follows the ocular involvement in all cases. Tinnitus, observed in approximately two-thirds of the patients, is the most important extraocular sign suggesting VKH diagnosis. Females make up 75% of patients, and the disease is present in the acute stage and incomplete form in half of the patients. Patients presenting in the acute stage and treated with high-dose corticosteroids are less prone to develop cutaneous signs and thus the complete form of the disease. On the other hand, although treated immediately, ocular findings representative of chronic stage may develop during the follow-up period in patients presenting with the acute stage. The chronic disease, either recurrent or not, is more prone to develop in lately diagnosed and/or inadequately treated patients. Fortunately, the disease has a quite good visual prognosis, with final VA of $\geq 20/40$ and no ocular inflammatory attack in $\sim 70\%$ of patients. An aggressive treatment with the use of corticosteroids and additional immunosuppressive agents is the preferred treatment approach in VKH patients. The favorable visual prognosis might be attributable to this aggressive treatment approach or ethnical and geographical differences.

DECLARATION OF INTEREST

The authors report no conflicts of interest. The authors alone are responsible for the content and writing of the paper.

REFERENCES

- Moorthy RS, Inomata H, Rao NA. Vogt-Koyanagi-Harada syndrome. *Surv Ophthalmol.* 1995;39:265–292.
- Read RW, Rao NA, Cunningham ET. Vogt-Koyanagi-Harada disease. *Curr Opin Ophthalmol.* 2000;11:437–442.
- Snyder DA, Tessler HH. Vogt-Koyanagi-Harada syndrome. *Am J Ophthalmol.* 1980;90:69–75.
- Norose K, Yano A. Melanoma specific Th1 cytotoxic T lymphocyte lines in Vogt-Koyanagi-Harada disease. *Br J Ophthalmol.* 1996;80:1002–1008.
- Sugita S, Sagawa K, Mochizuki M, et al. Melanocyte lysis by cytotoxic T lymphocytes recognizing the MART-1 melanoma antigen in HLA-A2 patients with Vogt-Koyanagi-Harada disease. *Int Immunol.* 1996;8:799–803.
- Rao NA. Mechanisms of inflammatory response in sympathetic ophthalmia and VKH syndrome. *Eye (Lond).* 1997;11:213–216.
- Yamaki K, Gocho K, Hayakawa K, et al. Tyrosinase family proteins are antigens specific to Vogt-Koyanagi-Harada disease. *J Immunol.* 2000;165:7323–7329.
- Read RW, Holland GN, Rao NA, et al. Revised diagnostic criteria for Vogt-Koyanagi-Harada disease: report of an international committee on nomenclature. *Am J Ophthalmol.* 2001;131:647–652.
- Rajendram R, Evans M, Rao NA. Vogt-Koyanagi-Harada disease. *Int Ophthalmol Clin.* 2005;45:115–134.
- Read RW, Rechodouni A, Butani N, et al. Complications and prognostic factors in Vogt-Koyanagi-Harada disease. *Am J Ophthalmol.* 2001;131:599–606.
- Rubsamen PE, Gass JD. Vogt-Koyanagi-Harada syndrome: clinical course, therapy, and long-term visual outcome. *Arch Ophthalmol.* 1991;109:682–687.
- Bykhovskaya I, Thorne JE, Kempen JH, et al. Vogt-Koyanagi-Harada disease: clinical outcomes. *Am J Ophthalmol.* 2005;140:674–678.
- Forster DJ, Rao NA, Hill RA, et al. Incidence and management of glaucoma in Vogt-Koyanagi-Harada syndrome. *Ophthalmology.* 1993;100:613–618.
- Kuo IC, Rechdouni A, Rao NA, et al. Subretinal fibrosis in patients with Vogt-Koyanagi-Harada disease. *Ophthalmology.* 2000;107:1721–1728.
- Al-Kharashi AS, Aldibhi H, Al-Fraykh H, et al. Prognostic factors in Vogt-Koyanagi-Harada disease. *Int Ophthalmol.* 2007;27:201–210.
- Tugal-Tutkun I, Ozyazgan Y, Akova YA, et al. The spectrum of Vogt-Koyanagi-Harada disease in Turkey: VKH in Turkey. *Int Ophthalmol.* 2007;27:117–123.
- Murthy SI, Moreker MR, Sangwan VS, et al. The spectrum of Vogt-Koyanagi-Harada disease in South India. *Int Ophthalmol.* 2007;27:131–136.
- Riddington L, Hall AJ, Tait B, et al. Vogt-Koyanagi-Harada syndrome in patients of Vietnamese ancestry. *Aust N Z J Ophthalmol.* 1996;24:147–149.
- Chee SP, Jap A, Bacsal K. Spectrum of Vogt-Koyanagi-Harada disease in Singapore. *Int Ophthalmol.* 2007;27:137–142.
- Tesavibul N, Sansanayuth W. Vogt-Koyanagi-Harada disease in Thai patients. *J Med Assoc Thai.* 2005;88:26–30.
- Ozdal P, Yazıcı A, Tufek M, Ozturk F. Epidemiology of uveitis in a referral hospital in Turkey. *Turk J Med Sci.* In press.
- Khairallah M, Zaouali S, Messaoud R, et al. The spectrum of Vogt-Koyanagi-Harada disease in Tunisia, North Africa. *Int Ophthalmol.* 2007;27:125–130.
- Yang P, Zhang Z, Zhou H, et al. Clinical patterns and characteristics of uveitis in a tertiary center for uveitis in China. *Curr Eye Res.* 2005;30:943–948.
- Yamaki K, Hara K, Sakuragi S. Application of revised diagnostic criteria for Vogt-Koyanagi-Harada disease in Japanese patients. *Jpn J Ophthalmol.* 2005;49:143–148.
- Tabbara KF, Chavis PS, Freeman WR. Vogt-Koyanagi-Harada syndrome in children compared to adults. *Acta Ophthalmol Scand.* 1998;76:723–726.
- Sugiura S. Some observations on uveitis in Japan, with special reference to Vogt-Koyanagi-Harada and Behcet diseases. *Nihon Ganka Gakkai Zasshi.* 1976;80:1285–1326.
- Yang P, Ren Y, Li B, et al. Clinical characteristics of Vogt-Koyanagi-Harada syndrome in Chinese patients. *Ophthalmology.* 2007;114:606–614.
- Rao NA, Gupta A, Dustin L, et al. Frequency of distinguishing clinical features in Vogt-Koyanagi-Harada disease. *Ophthalmology.* 2010;117:591–599.
- Lertsumitkul S, Whitcup SM, Nussenblatt RB, et al. Subretinal fibrosis and choroidal neovascularization in Vogt-Koyanagi-Harada syndrome. *Graefes Arch Clin Exp Ophthalmol.* 1999;237:1039–1045.
- Sukavatcharin S, Tsai JH, Rao NA. Vogt-Koyanagi-Harada disease in Hispanic patients. *Int Ophthalmol.* 2007;27:143–148.
- Ohno S, Minakawa R, Matsuda H. Clinical studies of Vogt-Koyanagi-Harada disease. *Jpn J Ophthalmol.* 1988;32:334–343.
- Rao NA. Treatment of Vogt-Koyanagi-Harada disease by corticosteroids and immunosuppressive agents. *Ocul Immunol Inflamm.* 2006;14:71–72.
- Read RW, Yu F, Accorinti M, et al. Evaluation of the effect on outcomes of the route of administration of corticosteroids in acute Vogt-Koyanagi-Harada disease. *Am J Ophthalmol.* 2006;142:119–124.
- Paredes I, Ahmed M, Foster CS. Immunomodulatory therapy for Vogt-Koyanagi-Harada patients as first-line therapy. *Ocul Immunol Inflamm.* 2006;14:87–90.
- Mondkar SV, Biswas J, Ganesh SK. Analysis of 87 cases with Vogt-Koyanagi-Harada disease. *Jpn J Ophthalmol.* 2000;44:296–301.
- Agarwal M, Ganesh SK, Biswas J. Triple agent immunosuppressive therapy in Vogt-Koyanagi-Harada syndrome. *Ocul Immunol Inflamm.* 2006;14:333–339.
- Arcinue CA, Radwan A, Lebanan MO, et al. Comparison of two different combination immunosuppressive therapies in the treatment of Vogt-Koyonagi-Harada syndrome. *Ocul Immunol Inflamm.* 2013;21:47–52.